

Sep. 1992

Clinical and Histologic Classification of Endometriomas Implications for a Mechanism of Pathogenesis

Farr Nezhat, M.D.
Camran Nezhat, M.D.
Christopher J. Allan, M.D.
Deborah A. Metzger, Ph.D., M.D.
Donald L. Sears, M.D.

One hundred eighty-seven consecutive patients with persistent ovarian cysts and endometriosis underwent laparoscopic evaluation and ovarian cystectomy. All patients had been followed for a minimum of 6 weeks prior to surgery. The cysts were identified initially to be endometriomas based on their gross appearance and the presence of endometriosis at other pelvic sites. Presumed endometriomas were classified into three types based on size, cyst contents, ease of removal of the capsule, adhesions of the cyst to other structures and location of superficial endometrial implants relative to the cyst wall. After clinical laparoscopic classification, the cysts were evaluated histologically without knowledge of the clinical assessment. Histologically small (<2 cm), superficial ovarian

From the Department of Obstetrics and Gynecology, Mercer University School of Medicine, Macon, and the Center for Special Pelvic Surgery, Atlanta, the Department of Pathology, Northside Hospital, Atlanta, Georgia, and the Division of Reproductive Endocrinology and Infertility, Department of Obstetrics and Gynecology, University of Connecticut Health Center, Farmington, Connecticut.

Address reprint requests to: Camran Nezhat, M.D., 5555 Peachtree Dunwoody Road, N.E., Suite 276, Atlanta, GA 30342.

cysts were always endometriomas, and the cyst wall was very difficult to remove (type I). Large cysts with easily removed walls were usually luteal cysts (type II). Large cysts with walls adherent in multiple areas adjacent to superficial endometriosis were generally endometriomas but some also had histologic characteristics of functional (luteal or follicular) cysts (types IIIa and IIIb). These findings led to the conclusion that superficial ovarian endometriosis is similar to endometriosis in extra-ovarian sites in that the formation of superficial cysts is limited in size by fibrosis and scarring. In contrast, large endometriomas may develop as a result of secondary involvement of functional ovarian cysts by the endometriotic process.

Introduction

The ovary is involved in approximately half of all women with endometriosis.¹ Like other sites that demonstrate involvement with endometriosis, the ovary may have superficial implants. However, the development of large endometriomas is most unusual outside the ovary. It is known that not all "chocolate" cysts demonstrate histologic evidence of endometriosis,² and our ability to prevent, diagnose and treat endometriomas would be enhanced by knowledge of their pathogenesis. The subject of this report is the clinical and histologic evaluation of hemorrhagic ovarian cysts found in patients with endometriosis, their classification and a possible theory about their formation.

In order to attempt to clarify some of the questions regarding endometriomas, we report clinical and histologic analyses of 216 presumed endometriomas obtained from 187 patients.

Materials and Methods

The study group consisted of 187 women (21-42 years of age; parity range, 0-6, with a mean of 0.64) evaluated and treated between January 1988 and January 1990 who at the time of laparoscopy had cysts that were suspicious for endometriomas. This suspicion was based on gross appearance plus the presence of endometriosis on other pelvic peritoneal surfaces. Presenting symptoms included pelvic pain or infertility. Pelvic examination or ultrasound revealed adnexal mass. Preoperative evaluation consisted of vaginal ultrasound assessment of the cystic mass and serum CA-125 measurement. After the cyst was diagnosed, hormone suppressive therapy was initiated depending on the patient's past medical history and the persistence and size of the cyst. Cysts that were >6 cm and multiloculated and had existed for more

than three months were not suppressed (25%). Most of the patients referred to us were already receiving suppressive hormonal therapy at initial evaluation. Suppressive therapy was continued for six to eight weeks at which time the cysts were reevaluated by vaginal ultrasonography. Resolution of cysts occurred in the vast majority of patients. Women with cysts that were unchanged in size were scheduled for diagnostic laparoscopy for further evaluation.

At laparoscopy pelvic washings were routinely obtained, and if the cyst had smooth walls, laparoscopic ovarian cystectomy was performed. The cysts included in this study were believed to be endometriomas based on clinical appearance (hemorrhagic cysts) and the presence of endometriosis at other pelvic sites.

The CO₂ laser (Coherent, Palo Alto, CA) combined with videolaparoscopy was used to treat small foci of endometriosis. Presumed endometriomas were removed by cystectomy to prevent recurrence of endometriosis while preserving ovarian function. Normal-appearing functional structures, nonhemorrhagic cysts and normal ovaries were not removed. The 216 presumed endometriomas were removed in the following manner. After gross evaluation for possible malignancy, the cyst contents were aspirated. Adhesions between the cyst and the lateral pelvic wall or bowel were lysed with the CO₂ laser, and the cyst was mobilized. An incision was made in the most dependent part of the cyst. Five to ten mL of diluted (20 IU ampule diluted in 200 mL lactated Ringer's) Pitressin (Parke-Davis, Morris Plains, NJ) was injected between the capsule of the cyst and the ovarian cortex (hydrodissection) to facilitate removal of the capsule and to achieve hemostasis in the ovarian bed. Using two pairs of grasping forceps and a suction irrigation probe (Karl Storz, Culver City, CA), the capsule was removed from the adjacent ovarian cortex. Hemostasis was obtained by CO₂ laser or a bipolar electrocoagulator. The capsules were sent for histologic evaluation. Some large cysts required partial oophorectomy. After cystectomy and hemostasis, the edges of the defect were approximated by low-power CO₂ laser, bipolar electrocoagulator, or, in some instances, with 4-0 polydioxanone suture (PDS, Ethicon, Inc., Somerville, NJ). All procedures were videotaped in their entirety for future reference.

These hemorrhagic cysts were classified by the surgeons prior to histologic evaluation using the following criteria: (1) size, (2) cyst contents, (3) ease of removal of the capsule, (4) adhesions of the cyst to other structures and (5) location of superficial endo-

metrial implants relative to the cyst wall (Figure 1). Microscopic evaluation was performed by pathologists C.A. and D.S., who were not aware of the clinical observations. Serial sections from multiple areas of the cysts were studied.

Results

On the basis of the clinical and histologic characteristics, three types of hemorrhagic cysts were identified (Table I).

Type I: Fifteen cysts, 1–2 cm in diameter (average, 1.67 cm), contained thick, brownish material. Removal of the cyst walls was difficult, but with persistence they were removed completely in segments. Microscopic examination showed that all had an endometrial lining. These small endometriomas showed hemosiderin deposition in 11 instances, and 5 showed fibrosis. Dense surface adhesions were found in five instances, and three had filmy adhesions.

Type II: Fifty-seven cysts, 2–6 cm in diameter (average, 3.9 cm), contained blood-tinged yellow fluid, gelatinous clots or thick, brownish material. The capsule separated easily from the surrounding ovarian tissue. Endometrial implants adjacent to the cyst on the ovarian surface were superficial but did not penetrate the cyst or its capsule. Some ovaries did not have any surface endometrial implants. On microscopic examination, a luteinized lining was found in 46 cysts. Six cysts showed fibrosis or hemosiderin in the wall, 5 had dense surface adhesions and 11 had filmy adhesions. Included in this group were two hemorrhagic cystic teratomas and nine hemorrhagic cysts with no residual identifiable lining. None of these 46 cyst walls had evidence of endometrial tissue.

Type IIIa: Forty-six cysts, 3–12 cm in diameter (average, 5.4 cm), were identified that contained brownish fluid and on occasion, degenerating blood clots. Ovarian surface endometrial implants were present—some close to the cyst wall. Removal of these cysts from the underlying ovarian tissue was relatively easy, except in the areas adjacent to foci of endometriosis where the capsule was adherent (Figure 2). On microscopic examination, a focal endometrial lining was present in 23 cysts; others in this group included 14 luteal cysts and 9 hemorrhagic cysts without residual diagnostic lining. Hemosiderin deposition and/or fibrosis were found in 35 instances. Twenty-two cysts had dense surface adhesions, and 13 others had filmy adhesions.

Type IIIb: Ovarian cysts removed from 98 patients

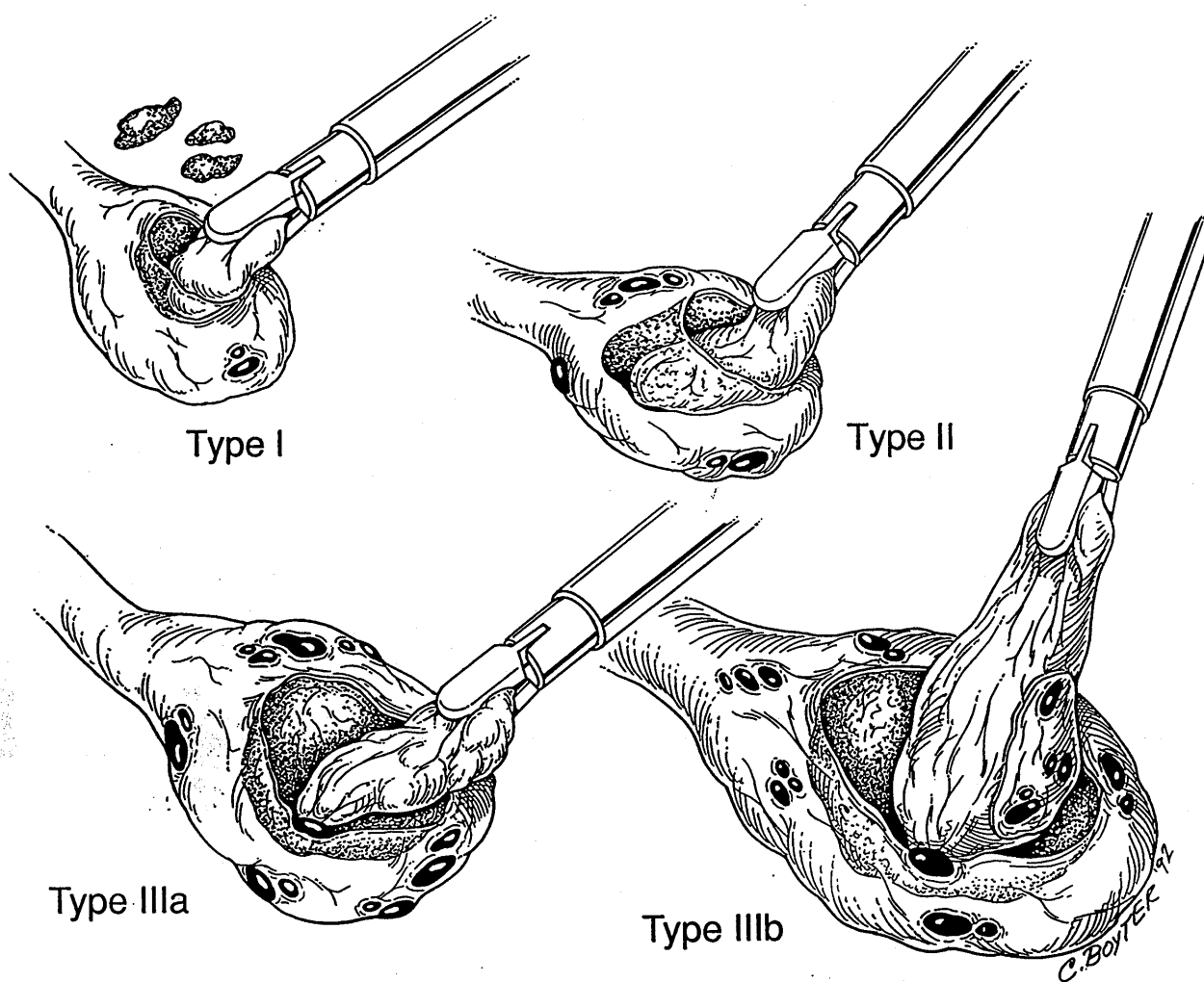


Figure 1
 Classification of hemorrhagic ovarian cysts by gross features and ease of removal. Type I. Small superficial endometrial cysts, removed piecemeal with difficulty. Type II. Cyst removed easily, endometriosis not adherent to cyst. Type IIIa. Cyst removed easily except where attached to endometriosis. Type IIIb. Cyst removed easily except where involved by penetrating endometriosis; partial removal of capsule may be necessary.

were 3–20 cm in diameter (average, 7 cm), and these cysts had thick, dark brownish contents. Ovarian surface endometrial implants were present and penetrated the cyst with capsular involvement in at least one area. The ovary was densely adherent to either the lateral pelvic wall or to the back of the uterus, and during separation the cyst often ruptured. Dense adhesions to adjacent structures were present in 88 instances, and 2 showed filmy surface adhesions. In some areas no plane between cyst and ovary could be developed, so that partial removal of the ovarian cortex along with the capsule was required. This type is differentiated from type IIIa by the inability to remove the capsule intact without removing adjacent

ovarian tissue. On microscopic examination multiple foci of endometrial lining were seen in 84 of these cysts. Other cysts in this group included 10 luteal cysts and 4 hemorrhagic cysts with no residual distinctive lining. Hemosiderin deposition and/or fibrosis were noted in 88 instances.

A few cysts were combinations of endometrial cysts and nonspecific hemorrhagic types. As they increased in size, there was increasing degeneration of the cells lining the cysts. The foci of endometrial lining were best demonstrated in areas with overlying implants and fibrosis. Only rarely did the endometrial layer completely line a large hemorrhagic cyst. The relationship between functional cysts and

Table I Characteristics of Presumed Endometriosis

Type	No.	Size (cm) (mean)	Luteal lining	Endometrial lining	No diagnostic lining	Adhesions (dense/filmy)	Hemosiderin and/or fibrosis
I	15	1-2 (1.67)	0	15	0	5/3	15
II	57	2-6 (3.9)	46	0	9	5/11	6
IIIa	46	3-12 (5.4)	14	23	9	22/13	35
IIIb	98	3-20 (7.0)	10	84	4	88/2	88

development of endometriosis is shown in Figures 3 to 6.

The morphologic and clinical differences observed in the different types were not a function of the type of hormonal suppressive therapy, because treatment regimens were distributed similarly within each cyst type.

Results are expressed as the mean \pm SD (CA-125 levels). Statistical analysis utilized the Student's *t*-test; the level of significance follows each value. The mean preoperative CA-125 levels for each cyst type were as follows: type I, 26.1 \pm 11.0, $P < .01$; type II, 40.8 \pm 20.5, $P < .05$; type IIIa, 32.0 \pm 14.0, $P < .05$; and type IIIb, 47.6 \pm 34.1, $P < .05$. Statistically significant differences are noted among all types except for types I and IIIa and types II and IIIb. However, we do not believe that CA-125 levels can be used pre-

operatively to differentiate between different types of cysts.

Discussion

Endometriosis is a hemorrhagic fibrotic process that leads to formation of adhesions and small cysts. While the precise mechanism for the development of endometriosis remains controversial, direct implantation appears to explain most cases.³ Endometriosis behaves differently in association with the ovary than at other sites, and the lining of the endometrioma seems to self-destruct with cyst enlargement.

Several explanations have been offered to explain the development of ovarian endometriomas. Sampson⁴ suggested that endometriomas may arise as a result of invasion of functional cysts by surface implants. Alternatively, endometrial lesions found deep

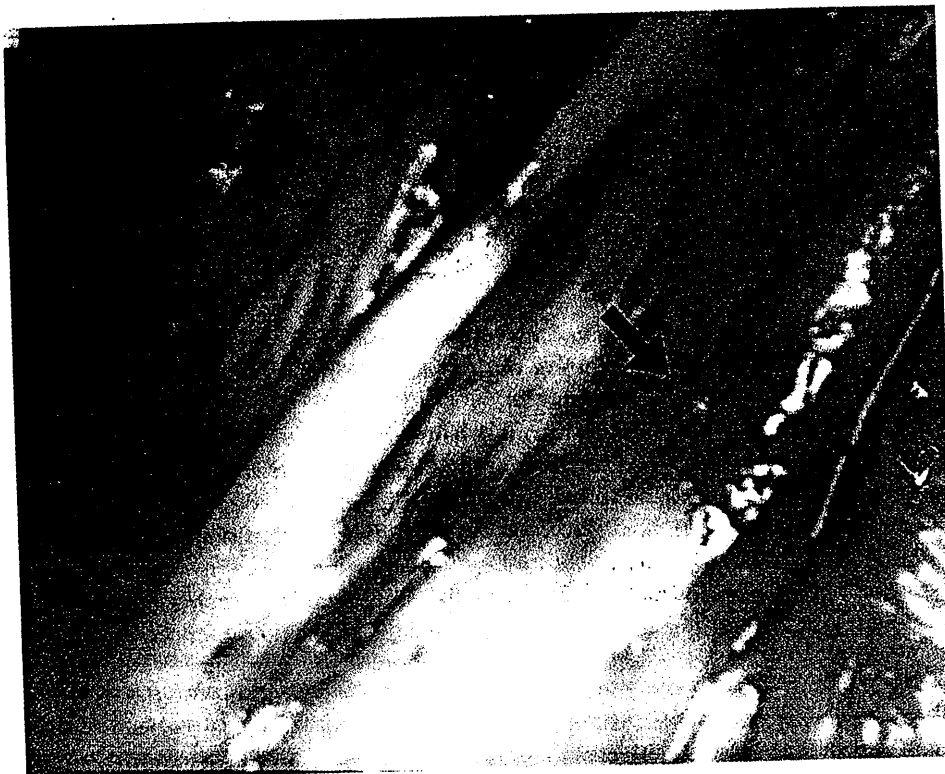


Figure 2
Type IIIa cyst removal. Yellow to red cyst (top) being readily stripped from underlying ovarian capsule except where adherent to focal endometriosis.

in the ovary could originate by metaplasia of celomic epithelium that lines the cystic epithelial inclusions frequently found in ovaries.⁵⁻⁷

Several physiologic processes are unique to the ovary that separate it from other pelvic sites where endometriosis is commonly found. First, the ovary contains high concentrations of ovarian steroids and growth factors, which may influence the initiation, maintenance and growth of endometrial implants. Second, the continuity of the ovarian surface is regularly interrupted by follicular rupture at the time of ovulation. Third, the ovary is subject to the formation of functional ovarian cysts, which tend to be self-limiting, but may temporarily alter the functional and structural integrity of the ovary.

In the course of performing operative endoscopy for the treatment of endometriosis, we observed that suspected endometriomas could be classified into three clinical types based on size, cyst contents, ease of removal of the capsule, adhesions of the cyst to other structures and the location of superficial implants of endometriosis relative to the cyst. When the histologic appearance was compared with the clinical classification, small superficial cysts that were difficult to remove were always endometriomas (type I); large cysts with walls that were easily removed were usually luteal cysts (type II); and large cysts that had adhesions or were associated with superficial endometriosis implants were often endometriomas, but some also had histologic characteristics of corpus luteum cysts (types IIIa and IIIb). Thus, cysts of pure types (endometrioma or luteal) as well as mixed types were encountered and were distinguishable based on adherence of the capsule to the

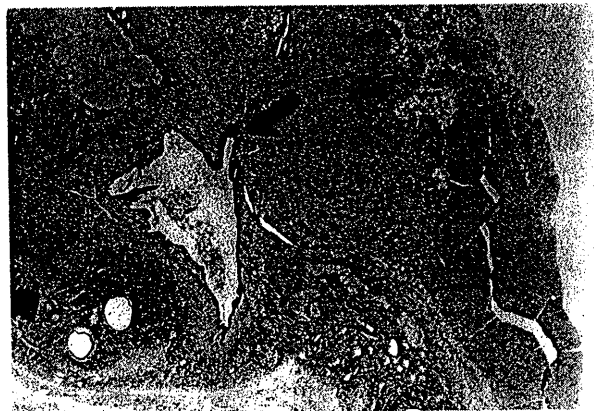

Figure 3
Endometriosis (left) extending into wall of luteal cyst (right) (hematoxylin and eosin, $\times 10$).




Figure 4
Hemorrhagic follicle cysts (left) extending into endometrial cyst (right) (hematoxylin and eosin, $\times 3$).

ovarian cortex. The presence of endometriosis on the ovarian surface, particularly in the presence of dense adhesions, was associated with the absence of tissue planes between the capsule and the ovarian stroma, giving the impression that the surface endometriosis may have invaded the functional ovarian cyst. On histologic examination, variable degrees of "invasion" of the cyst wall by the surface endometriosis could be observed, thus forming the basis of the differentiation between types IIIa and IIIb cysts, type IIIa cysts showing early signs of "invasions" and type IIIb demonstrating more advanced association between the surface endometriosis and the cyst wall.

"Pure" endometriomas develop from surface endometriosis. Based on the microscopic findings in our study, it seems reasonable to assume that large ovarian endometriomas result from secondary involvement of hemorrhagic nonendometrial cysts by endometriosis. Large primary ovarian endometriomas may be exceptional because of adjacent scarring and adhesions, which would limit their size.

These observations may explain the variable response of presumed ovarian endometriomas to medical therapy, the rarity of large cystic endometriomas in sites other than the ovary and the infrequency of torsion of endometriomas because of associated adhesions. In addition, we have noted a lack of development of large endometriomas in patients on ovulation suppressive therapy despite the development of small surface implants.

Support for this theory of endometrioma formation comes from several observations. First, luteal lining and endometrial lining are found in different areas of large chocolate cysts, although in this series

we were unable to demonstrate a transition with residual luteal tissue underlying an endometrial cyst lining. However, we presented photomicrographs showing endometriotic tissue that appears to be encroaching on an area of luteal cells as well as a follicular cyst extending into an endometrial cyst.

Second, Martin and Berry² also observed that 27% of cysts that they assumed to be endometriomas on clinical appearance were hemorrhagic luteal cysts on histologic examination. Our findings were similar in that 32% of presumed endometriomas were later histologically confirmed to be corpora lutea. However, Martin and Berry² did not report any mixed-cellular types, possibly because serial sections were not done.

Finally, our findings and theory are supported by the observations of Sampson, who 70 years ago noted "At operation the cyst or ovary is found adherent and in freeing it the chocolate contents escape because a previous perforation reopened or the cyst is torn. The histologic findings in these cysts vary in different portions of the same cyst. A portion (usually deeper) . . . is lined by a luteal membrane. The rest of the cyst, usually toward the perforation, is apparently being relined by the invasion of epithelium, through the perforation, from epithelium situated in the periphery of the ovary at the site of rupture. With the advance of the epithelial invasion, the luteal membrane retrogresses and eventually the entire cyst may be relined by this epithelial tissue."⁴




Figure 5
Lining of follicle cyst in Figure 4 (hematoxylin and eosin, $\times 100$).



Figure 6
Lining of endometrial cyst in Figure 4 (hematoxylin and eosin, $\times 100$).

Our observations have extended those of Sampson to include additional clinical observations that may aid in preliminary diagnosis of the type of cyst at surgery.

The ability to classify endometriomas may enhance additional studies of their etiology and pathophysiology and provide possible methods to prevent and treat endometriosis and ovarian endometriomas.

Acknowledgment

We gratefully acknowledge the editorial assistance of Alvin M. Siegler, M.D., of the University of New York and Health Science Center of Brooklyn, New York.

References

1. Jenkins S, Olive DL, Haney AF: Endometriosis: Pathogenic implications of the anatomic distribution. *Obstet Gynecol* 67:335, 1986
2. Martin DC, Berry JD: Histology of chocolate cysts. *J Gynecol Surg* 6:43, 1990
3. Metzger DA, Haney AF: Etiology of endometriosis. *Obstet Gynecol Clin North Am* 16:1, 1989
4. Sampson JA: Perforating hemorrhagic (chocolate) cysts of the ovary. *Arch Surg* 3:245, 1921
5. Blaustein A, Kantius M, Kaganowicz A, et al: Inclusions in ovaries of females aged day 1-30 years. *Int J Gynecol Pathol* 1:145, 1982
6. Woodruff JD, Julian CG: Explorations into the genesis of ovarian malignancy. *Int J Gynaecol Obstet* 8:587, 1970
7. Kerner H, Gatton E, Czernobilsky B: Unusual ovarian, tubal and pelvic mesothelial inclusions in patients with endometriosis. *Histopathology* 5:277, 1981