

## Is hormonal treatment efficacious in the management of ovarian cysts in women with histories of endometriosis?

Ceana H.Nezhat<sup>1,2</sup>, Farr Nezhat<sup>1,2</sup>, Soheila Borhan<sup>3</sup>, Daniel S.Seidman<sup>2</sup> and Camran R.Nezhat<sup>1,2,4,5</sup>

<sup>1</sup>Department of Obstetrics and Gynecology, Mercer University School of Medicine, Macon, GA; <sup>2</sup>Department of Obstetrics and Gynecology, Stanford University School of Medicine, Stanford, CA; <sup>3</sup>Department of Obstetrics and Gynecology, Louisiana State University, New Orleans, LA and <sup>4</sup>Department of Surgery, Stanford University School of Medicine, Stanford, CA, USA

<sup>5</sup>To whom correspondence should be addressed at: 900 Welch Road, Suite 405, Palo Alto, California 94304, USA

**In a controlled, randomized study, we evaluated the effectiveness of various hormonal regimens in treating 70 women (mean age  $34.7 \pm 5.7$  years) who had unilateral or bilateral ovarian cysts presumed to be physiological (functional) and a history of endometriosis. The patients were assigned randomly to one of the following groups: group I (control), no treatment; group II, oral contraceptives (35 µg ethinyl oestradiol and 1 mg norethindrone); group III, oral contraceptives (50 µg ethinyl oestradiol and 1 mg norethindrone); group IV, danazol 800 mg/day. Serum CA-125 concentrations were measured in 32 women. All medications were taken continuously for 6 weeks. Subjects were re-evaluated by pelvic examination and transvaginal ultrasound. Those with persistent cysts were offered diagnostic and possible operative laparoscopy. As 11 patients did not complete the study and five did not follow-up, the final study population comprised 54 women. At 6 weeks follow-up, complete resolution of cysts was found in: group I, 12 out of 18 (66.7%); group II, five out of nine (55.6%); group III, eight out of 14 (57.1%); and group IV, seven out of 13 (53.9%). Two of the 22 women with persistent cysts opted for 6 weeks further medical therapy and achieved complete resolution; 19 underwent laparoscopy, and one was lost to follow-up. All laparoscopic findings revealed benign masses. We found no statistically significant effect when hormonal treatment was compared with expectant management. There was no correlation between serum CA-125 concentrations and the persistence or resolution of cysts.**

**Key words:** endometriosis/hormonal suppressive therapy/physiological ovarian cyst

### Introduction

Women with histories of endometriosis frequently have ovarian cysts identified on physical or ultrasound examination. It is accepted that the only effective treatment for an endometrial cyst is excision, because these cysts do not completely resolve with hormone therapy (Donnez *et al.*, 1994). In women of

reproductive age, most ovarian cysts are physiological, either follicular cysts or corpora lutea (DeWilde *et al.*, 1989). As the clinical distinction between endometriomas and physiological cysts is difficult (Brosens *et al.*, 1994), expectant management is recommended for 6–8 weeks, provided the ultrasonographic characteristics of the ovarian mass are benign (Lipitz *et al.*, 1992). Some have advocated the use of oral contraceptives containing oestrogen and progesterone for 6 weeks, to aid in distinguishing between physiological and pathological ovarian cysts (Spanos, 1973). Randomized controlled trials in women undergoing ovulation induction did not prove that ovarian cyst resolution is affected by oral contraceptives (Steinkampf *et al.*, 1990; Ben-Ami *et al.*, 1993; Turan *et al.*, 1994).

We assessed the rate of ovarian cyst persistence in women with histories of endometriosis, comparing expectant management, oral contraceptives, and danazol. Oral contraceptives containing two different amounts of oestrogen were used as it has been suggested that their effect depends on the amount of oestrogenic component (Goldzieher, 1989). Danazol was included because it is the hormonal agent most frequently used to treat endometriosis (Barbieri *et al.*, 1982; Dmowski, 1990; Damaria and Rock, 1994).

### Materials and methods

A total of 70 women with surgically confirmed histories of endometriosis were included in the study. Of these 70 women, five did not follow-up after the initial diagnosis, and 11 did not complete the study. The cysts were diagnosed during pelvic examination or vaginal ultrasound performed to evaluate pelvic pain ( $n = 39$ ), ovarian stimulation ( $n = 5$ ), initial infertility workup ( $n = 4$ ), or routine gynaecological examination ( $n = 6$ ). All cysts were  $\geq 1.6$  cm in diameter, and none had thick septa, papillations, or associated ascites. If the cyst was diagnosed at any time other than during the first week of the menstrual cycle, the woman was re-evaluated and the ultrasound repeated during the first week of her next menstrual cycle to exclude normal follicles and corpora lutea. All ultrasound scans were performed in a gynaecological office and confirmed by one of the senior authors. Women who were on hormonal suppressive therapy, i.e. danazol, gonadotrophin-releasing hormone (GnRH) agonist, or who had a solid ovarian tumour at the time of diagnosis also were excluded from this study.

The subjects were randomly assigned to one of four groups using computer-generated random tables and closed envelopes. All women were informed of their treatment options, including possible side-effects of the medication, and consented to participate in the study. Group I ( $n = 18$ ) was expectantly managed and served as a control. Group II ( $n = 9$ ) and group III ( $n = 14$ ) received two different types of oral contraceptives containing either 35 or 50 µg respectively of ethinyl oestradiol and 1 mg norethindrone continuously for 6 weeks. Group IV ( $n = 13$ ) received 800 mg of danazol daily for 6 weeks.

**Table I.** Patient information and summary of results in control and hormonally-treated groups

	Group I		Group II		Group III		Group IV	
	No. patients	Percentage	No. patients	Percentage	No. patients	Percentage	No. patients	Percentage
No. patients	18		9		14		13	
Age (years) mean	35.3		35.3		33.6		34.9	
SEM	±5.0		±5.6		±6.5		±5.6	
Ovulation induction	3	16.7	0	0	1	7.1	1	8
Cyst size mean	3.4		3.6		3.9		4.7	
SEM	±1.1		±1.1		±1.1		±1.3	
Resolved	12	66.7	5	55.6	8	57.1	7	53.9
Persistent	6	33.3	4	44.4	6	42.9	6	46.1
Physiological	2		1 <sup>a</sup>		1 <sup>b</sup>		1	
Endometriomas	3 (1 <sup>c</sup> )		2 (1 <sup>d</sup> )		5 (1 <sup>c</sup> )		3	
Other	0	1 benign simple cyst <sup>a</sup> 1 hydrosalpinx <sup>c</sup>	1 adhesion <sup>b</sup>		1 lost to follow-up <sup>c</sup>			

<sup>a</sup>Patient had benign simple cyst and two contralateral follicular cysts. The benign simple cysts developed during the 6 week treatment.

<sup>b</sup>Patient had adhesions and contralateral corpus luteum.

<sup>c</sup>Bilateral.

<sup>d</sup>Patient had unilateral endometriomas.

**Table II.** Ovarian cyst size and outcome of therapy at 6 weeks

Group	I		II		III		IV		Overall	
	<3	≥3	<3	≥3	<3	≥3	<3	≥3	<3	≥3
Cyst size (cm)										
Number	5	15	4	8	5	11	1	13	15	47
Persistence rate (%)	20	40	100	38	60	46	0	46	60	43

**Table III.** Presenting symptom and outcome

Presenting symptom	No. of women	No. of cysts	Persistent cysts		Pathology
			No.	Percentage	
Pain*	39	45	24	53.3	13 endometriomas (two bilateral) 6 physiological (one unilateral) 2 hydrosalpinges (bilateral) 1 adhesion 1 resolved following 6 weeks treatment with danazol 1 lost to follow-up
Infertility follow-up* treated with clomid and/or pergonal	5	6	0	0	
Routine gynaecological examination	4	5	2	40	2 endometriomas (unilateral)
Initial infertility workup	4	4	1	25.0	1 resolved following 6 weeks treatment with danazol
Abnormal uterine bleeding	2	2	1	50.0	1 endometrioma

\*Fisher's exact test ( $P = 0.012$ ) shows a significant difference between the pain and the infertility groups.

All women were re-evaluated by pelvic examination and transvaginal ultrasound 6 weeks after beginning the protocol. If the cyst(s) persisted, diagnostic and possible operative laparoscopy was recommended (Nezhat *et al.*, 1995). Serum CA-125 was obtained randomly from 32 women to determine whether there was any correlation with cyst persistence or resolution.

### Statistical analysis

Study outcomes were analysed using  $\chi^2$  or Fisher's exact test for categorical data and Student's *t*-test for continuous variables.  $P < 0.05$  was considered to be statistically significant.

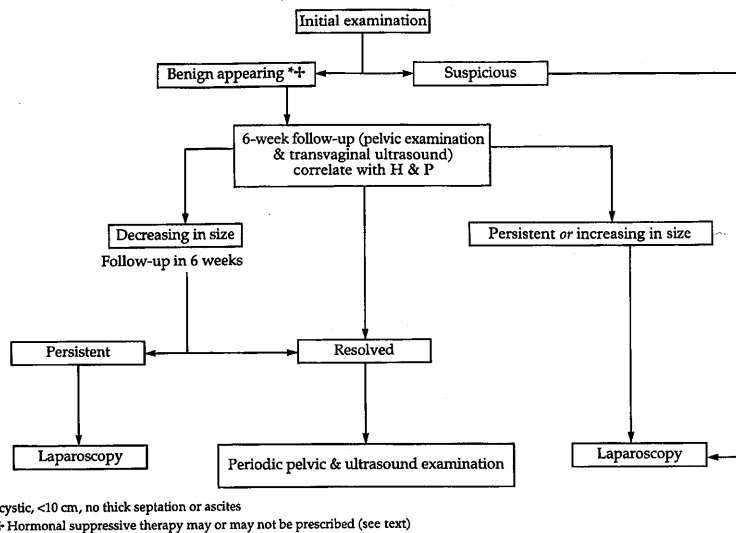
### Results

Among the four groups, there was no significant difference in the mean age or the mean diameter of the cysts (Table I). In group I, 12 of the 18 patients (66.7%) had complete resolution of their cysts with expectant management at 6 weeks follow-

up. Five of the six women with persistent cysts underwent laparoscopy, which revealed one corpus luteum, one follicular cyst, and four endometriomas (three women) (Table I). One woman requested medical treatment before laparoscopy; she received danazol 800 mg/day, and the cyst resolved in 6 weeks.

Five of the nine women (55.6%) in group II had complete resolution at follow-up. One experienced a recurrence 9 months later in the same ovary. Laparoscopy was performed, and a haemorrhagic corpus luteum was found. The four women with persistent cysts underwent laparoscopy. Three endometriomas (two women), one benign simple cyst with two follicular cysts (one woman), and bilateral hydrosalpinges (one woman) were revealed.

In group III, eight of the 14 women (57.1%) had complete resolution of their cysts after 6 weeks of continuous treatment. All women with persistent cysts underwent laparoscopy. We found that one woman had a corpus luteum and adhesions on



**Figure 1.** Protocol for benign appearing ovarian cyst management in pre-menopausal women.

**Table IV.** Serum CA-125 concentration (IU/ml) for women with persistent versus resolved cysts

	Group I (n = 7)	Group II (n = 6)	Group III (n = 11)	Group IV (n = 6)	Total (n = 32)
Resolved cysts					
no.	4	4	6	5	19
range	<5-14	<5-20	<5-32	10-30	<5-32
mean ± SD	8.8 ± 3.3	9.75 ± 6.0	12.7 ± 9.2	23.4 ± 7.6	14.1 ± 9.2
Persistent cysts					
no.	3	2	5	3	13
range	<5-22	30-43	12-101	7-36	<5-101
mean ± SD	10 ± 4.6	36.5 ± 6.5	48 ± 34.2	17.3 ± 13.2	30.4 ± 27.6

the contralateral ovary that appeared to be a cyst at ultrasound, and five had endometriomas (one bilateral).

Of the 13 women in group IV, seven (53.9%) had complete resolution of their cyst(s) at 6 weeks follow-up. One woman's cyst decreased in size but did not resolve completely. Because she experienced side-effects to danazol, her dosage was reduced from 800 to 600 mg/day. After 1 month, her cyst had resolved. Four of the five women with persistent cysts underwent laparoscopy. One had a follicular cyst and three had endometriomas. One was lost to follow-up.

Of the five women with bilateral ovarian cysts, none had complete resolution. One patient's right cyst resolved and the left one decreased in size. She was then lost to follow-up. The remaining four women with persistent cysts underwent laparoscopy. Two had bilateral endometriomas, one had bilateral hydrosalpinges, and one had a corpus luteum on one ovary and adhesions surrounding the contralateral ovary.

Of the 22 women with persistent cysts at 6 weeks follow-up, two experienced complete resolution after an additional 6 weeks of medical therapy with danazol. Of the 19 women who underwent laparoscopy, only five (26.3%) had physiological cysts. All five women who had received ovulation medications experienced complete resolution.

The rates of cyst persistence, according to size (<3 and ≥ 3 cm) after 6 weeks, are shown in Table II. The persistence rate was not significantly different for larger cysts.

As shown in Table III, the outcome differed by the presenting symptom. Women undergoing ovulation induction in previous months had a high rate of ovarian cyst resolution.

Serum CA-125 concentrations for the four study groups are shown in Table IV, stratified by resolution or persistence at 6 weeks follow-up. Although the CA-125 concentrations were slightly higher for women with persistent cysts, the difference was not statistically significant.

## Discussion

The effect of oral contraceptives and danazol on the resolution rate of ovarian cysts was assessed. The five women who had been treated with ovulation medications before developing ovarian cysts experienced complete resolution at 6 weeks follow-up, regardless of the management method. Of the remaining 49 women, 22 had persistent cysts at 6 weeks follow-up. Two women opted for further medical therapy and experienced complete resolution after an additional 6 weeks of treatment with danazol. We concluded that the remaining 27 women who experienced complete resolution probably had physiological cysts; they responded equally to medical and expectant management. At laparoscopy, we found 16 endometriomas, six physiological cysts, and one organic cyst. Of those women whose cysts originally resolved, three recurred and were confirmed to be endometriomas. Studies have shown that endometriomas >2 cm are presumed to be physiological cysts invaded by superficial cortical endometriosis (Nezhat *et al.*, 1992a).

We were unable to demonstrate a significant difference between the use of hormonal suppression and expectant management in treating physiological ovarian cysts. A high rate

of cyst resolution after 6 weeks was found not only in those who received ovulation induction medication, but also in those who developed cysts spontaneously. This is in agreement with the findings of Steinkampf *et al.* (1990) and Ben-Ami *et al.* (1993) whose studies showed no significant effect of hormonal treatment on ovarian cysts in women who had recently undergone ovulation induction. Overall resolution rates were lower than in previous studies (Steinkampf *et al.*, 1990; Ben-Ami *et al.*, 1993), reflecting the expected high incidence of endometriomas in endometriosis patients. It is important to keep in mind that these numbers are not large enough to draw definitive conclusions.

Clinicians are often challenged by the occurrence of symptomatic and asymptomatic ovarian cystic masses in pre-menopausal women. The main concern has been the presence of malignancy, but this incidence is very low (Nezhat *et al.*, 1992b). In pre-menopausal women (especially those who desire future child-bearing), one consideration is preserving ovarian function by avoiding unnecessary surgery on the ovaries. Although cystectomy is possible in most ovarian cysts when there is a desire to preserve the ovary (Nezhat *et al.*, 1992a; Canis *et al.*, 1994), aggressive traumatization of the ovaries can be associated with adhesion formation (Nezhat and Nezhat, 1991; Canis *et al.*, 1992), and consequently infertility and pelvic pain. This need for restraint is underscored by our findings in a series of 13 women who had ovarian remnant syndrome (Nezhat and Nezhat, 1992b). In five (39%), the initial surgical procedure was removal of follicular or luteal cysts. Therefore, when treating ovarian cysts in pre-menopausal women, the first question to be answered is whether the cyst is pathological and should be removed, or physiological (follicular or luteal), which could resolve spontaneously.

Most persistent cysts in women with endometriosis are endometriomas, although the presence or coexistence of physiological cysts (follicular or corpus luteum) is not uncommon, and the reported frequency varies (Martin and Berry, 1990; Fayez and Vogel, 1991; Nezhat *et al.*, 1992a; Nezhat and Nezhat, 1992a; Brosens *et al.*, 1994). While some specific characteristics may be noted at laparoscopy (Nezhat *et al.*, 1992a; Cahis *et al.*, 1992; Nezhat and Nezhat, 1992a), an accurate diagnosis is usually only made histologically.

Although hormonal suppressive therapy does not appear to be effective in resolving the functional physiological cyst, women who require laparoscopy and wish to preserve their ovaries may benefit from the treatment. Preoperative suppression of ovarian function will decrease the vascularization and minimize trauma to the ovary. Our protocol for ovarian cyst management in pre-menopausal women is detailed in Figure 1.

## References

- Barbieri, R.L., Evans, S. and Kistner, R.W. (1982) Danazol in the treatment of endometriosis: analysis of 100 cases with a 4-year follow-up. *Fertil. Steril.*, **37**, 737-746.
- Ben-Ami, M., Geslevich, Y., Ba, S. *et al.* (1993) Management of functional ovarian cysts after induction of ovulation. A randomized prospective study. *Acta Obstet. Gynecol. Scand.*, **72**, 396-397.
- Brosens, I.A., Puttemans, P.J., Deprest, J. (1994) The endoscopic localization of endometrial implants in the ovarian chocolate cyst. *Fertil. Steril.*, **61**, 1034-1038.
- Canis, M., Mage, G., Wattiez, A. *et al.* (1992) Second-look laparoscopy after laparoscopic cystectomy of large ovarian endometriomas. *Fertil. Steril.*, **58**, 617-619.
- Canis, M., Mage, G., Pouly, J.L. *et al.* (1994) Laparoscopic diagnosis of adnexal cystic masses: a 12-year experience with long-term follow-up. *Obstet. Gynecol.*, **83**, 707-712.
- Damaria, M.A. and Rock, J.A. (1994) Goserelin (Zoladex) versus danazol for endometriosis: the North American experience. *Br. J. Obstet. Gynaecol.*, **101** (suppl.), 13-18.
- DeWilde, R., Bordt, J., Hesseling, M. and Vancaillie, T. (1989) Ovarian cystotomy. *Acta Obstet. Gynecol. Scand.*, **68**, 363-364.
- Dmowski, P. (1990) Danazol: a synthetic steroid with diverse biologic effects. *J. Reprod. Med.*, **35**, 69-75.
- Donnez, J., Anaf, V., Nisolle, M. *et al.* (1994) Ovarian endometrial cysts: the role of gonadotrophic-releasing agonist and/or drainage. *Fertil. Steril.*, **62**, 63-66.
- Fayez, J.A. and Vogel, M.F. (1991) Comparison of different treatment methods of endometriomas by laparoscopy. *Obstet. Gynecol.*, **78**, 660.
- Goldzieher, J. (1989) *Hormonal Contraception: Pills, Injections and Implants*. Essential Medical Information Systems Inc., San Antonio, pp. 9-267.
- Lipitz, S., Seidman, D.S., Menczer, J. *et al.* (1992) Recurrence rate after fluid aspiration from sonographically benign-appearing ovarian cysts. *J. Reprod. Med.*, **37**, 845-848.
- Martin, D.C. and Berry, J.D. (1990) Histology of chocolate cysts. *J. Gynecol. Surg.*, **6**, 43.
- Nezhat, C. and Nezhat, F. (1991) Postoperative adhesion formation after ovarian cystectomy with and without ovarian reconstruction. Presented at American Fertility Society Annual Meeting, Orlando, Florida, October 21, 1991.
- Nezhat, C. and Nezhat, F. (1992a) Comparison of different treatment methods of endometriomas by laparoscopy. Letter to the editor. *Obstet. Gynecol.*, **79**, 315.
- Nezhat, C. and Nezhat, F. (1992b) Operative laparoscopy for the management of ovarian remnant syndrome. *Fertil. Steril.*, **57**, 1003-1007.
- Nezhat, F., Nezhat, C., Allan, C.J. *et al.* (1992a) A clinical and histologic classification of endometriomas: implications for a mechanism of pathogenesis. *J. Reprod. Med.*, **37**, 771-776.
- Nezhat, C., Nezhat, F., Welander, C.E. and Benigno, B. (1992b) Four ovarian cancers diagnosed during laparoscopic management of 1,011 adnexal masses. *Am. J. Obstet. Gynecol.*, **167**, 790-796.
- Nezhat, C.R., Nezhat, F.R., Luciano, A.A. *et al.* (eds.) (1995) *Operative Gynecologic Laparoscopy: Principles and Techniques*. McGraw-Hill, New York, pp. 153-163.
- Spanos, W.J. (1973) Preoperative hormonal therapy of cystic adnexal masses. *Am. J. Obstet. Gynecol.*, **116**, 551-556.
- Steinkampf, M.P., Hammond, K.R. and Blackwell, R.E. (199) Hormonal treatment of functional ovarian cysts: a randomized, prospective study. *Fertil. Steril.*, **54**, 775-777.
- Turan, C., Zorlu, C.G., Ugur, M. *et al.* (1994) Expectant management of functional ovarian cysts: an alternative to hormonal therapy. *Int. J. Gynecol. Obstet.*, **42**, 257-260.

Received on October 10, 1995; accepted on February 1, 1996