

JOURNAL OF LAPAROENDOSCOPIC SURGERY  
Volume 1, Number 3, 1991  
Mary Ann Liebert, Inc., Publishers

## Laparoscopic Ovarian Cystectomy During Pregnancy

FARR NEZHAT, M.D., F.A.C.O.G., CAMRAN NEZHAT, M.D., F.A.C.O.G.,  
SHERYL L. SILFEN, M.D., and STEPHEN H. FEHNEL, M.D.

### ABSTRACT

A pregnant woman with a history of endometriosis and persistent bilateral adnexal masses underwent laparoscopic ovarian cystectomies at 16 weeks of gestation. There were no adverse sequelae, and the patient had an otherwise uneventful pregnancy and delivery. Operative laparoscopy should be considered to replace laparotomy in appropriate cases during pregnancy.

### INTRODUCTION

OPERATIVE LAPAROSCOPY HAS BEGUN to replace laparotomy for thousands of women with benign pelvic disease. The advantages of laparoscopy are obvious, including outpatient management or shorter hospital stay, reduced recovery time, less pain, and decreased cost. One group of young women, however, those who are pregnant, have not yet benefitted from the advances of operative laparoscopy.

### CASE REPORT

A 28-year-old female, gravida 1, para 0, was followed by serial ultrasound for ovarian cysts first noted during the menstrual cycle in which she conceived. At 16 weeks of gestation the adnexal masses persisted; preoperative ultrasound demonstrated a  $7.2 \times 6.8$  cm simple cyst on the right adnexa and a  $4.6 \times 4.6$  cm simple cyst on the left. A decision was made to proceed with operative laparoscopy (videolaseroscopy).

Past medical history was significant for endometriosis noted on exploratory laparotomy, with left ovarian cystectomy 3 years prior to admission. Postoperatively, a 6-month course of danazol suppressive therapy was instituted, followed by cyclic oral contraceptives until the patient wished to conceive. Interval pelvic examinations revealed no adnexal masses, but pelvic pain did prompt an emergency room visit one year prior to admission.

Informed consent accepted by the patient included information to the patient that spontaneous abortion or premature labor could result from any surgery, including laparoscopy, performed during pregnancy. She was further informed that operative laparoscopy was not, at this time, standard management, that, in spite of her history of endometriosis, there was a chance that the lesion could be ovarian cancer, and that intraoperative manipulation might worsen her prognosis.

## NEZHAT ET AL.

After induction of general endotracheal anesthesia, the patient was placed in a modified dorsolithotomy position. The Verres needle was inserted in the midline, 6 cm above the umbilicus, and saline was injected and aspirated to verify intraperitoneal placement; pneumoperitoneum was then established at a pressure of less than 10 mmHg. The laparoscope was inserted at the site of the Verres needle puncture. Three additional trocars were then inserted under direct visualization; the level of the umbilicus was selected to be safely above the uterine fundus, and the 5 mm trocars were inserted bilaterally and midline. The suction/irrigation probe and atraumatic grasping forceps were then inserted through these portals. No intracervical instruments were placed, and the uterus was manipulated gently with intra-abdominal instruments. Findings were large bilateral ovarian cysts and left-sided pelvic adhesions. Pelvic washings for cytology were obtained initially. The right ovarian cyst, 8 cm in diameter (Fig. 1), was then aspirated; chocolate material was obtained and sent for cytology. Using the CO<sub>2</sub> laser (40–80 W, superpulse mode) the cyst wall was then bivalved (Fig. 2), inspected, and removed as previously described.<sup>1</sup> The base of the cyst was vaporized with low-power laser (10–20 W) in continuous mode, and Kleppinger bipolar cautery forceps to achieve hemostasis. On the left, a 5 cm endometrioma was adherent to the pelvic side wall and bowel (Fig. 3). After adhesiolysis, this cyst was managed in the same manner as the former one. Ringer's lactate solution was used during the entire procedure for suction and irrigation of the cyst contents and blood clot debris. At the end of the procedure no medical adjuvants were used.

This procedure lasted approximately 1 hour and 25 minutes. Pelvic examination at the end of the procedure revealed the cervix to be long and closed. Pathologically, bilateral benign hemorrhagic cysts with decidualosis, suggestive but not diagnostic of endometriosis were noted. Cytology of pelvic washing and of cyst aspirate was negative.

Postoperatively the patient was managed with small doses of meperidine. Hematocrit was stable. She was observed overnight in the hospital and released the next morning. No tocolytic agents were used.

The remainder of the pregnancy was uneventful. At 38 weeks of gestation the patient underwent spontaneous labor and vaginal delivery of a healthy male infant, who at 5-month follow up is doing well.

## DISCUSSION

Persistent adnexal masses occur in 1 of every 556 pregnancies. A third of these masses are benign cystic teratomas, a third are persistent corpus luteum cysts, and less than 3% are malignant.<sup>2</sup> It has been the standard recommendation that any mass  $\geq$  6 cm which persists to the second trimester be removed by laparotomy, to prevent surgical emergencies such as torsion, rupture, and obstruction of labor, and to rule out ovarian cancer.

To avoid the need for laparotomy for benign disease during pregnancy, some authors have advocated selective conservative management of masses based on ultrasound findings.<sup>3</sup> Yet this approach would leave uncertainty about the diagnosis, and add psychological stress to the patient. Additionally, a large number of women would then have to undergo surgery in the immediate postpartum period, an even more stressful experience for a new mother. Operative laparoscopy with tissue sampling for definitive diagnosis, and ovarian cystectomy or oophorectomy seems the wiser choice. Should a tumor suspicious for malignancy be encountered at laparoscopy, exploratory laparotomy could be performed promptly.

To our knowledge, no other case reports of operative laparoscopy in pregnancy for management of adnexal mass have been published. A recent series of laparoscopic appendectomies in pregnancy, however, did report one case in which a large ovarian cyst, found incidentally, was removed using "puncture, ligation, and extirpation before appendectomy."<sup>4</sup> The appendectomy series, which included pregnant women from 8 to 25 weeks of gestation, fails to describe a method of trocar placement or complications. Uterine puncture at the time of Verres needle insertion could produce amniotic fluid leakage or infection; CO<sub>2</sub> insufflation into the uterine cavity has been suspected of causing gas embolism following pregnancy termination,<sup>5</sup> and is a theoretical risk in ongoing pregnancy as well. Open laparoscopy, using a Hassan cannula placed well above the uterine fundus, probably is preferable to the method described above; once the laparoscope is in place, abdominal placement can be confirmed prior to CO<sub>2</sub> insufflation.

In addition to the well-accepted practical advantages of laparoscopy over laparotomy, including reduced pain and improved cost effectiveness, there are some theoretical advantages specific to pregnant patients.




FIG. 1. Laparoscopic view of the large right ovarian cyst.



FIG. 2. Dissection and bivalving of cyst wall.

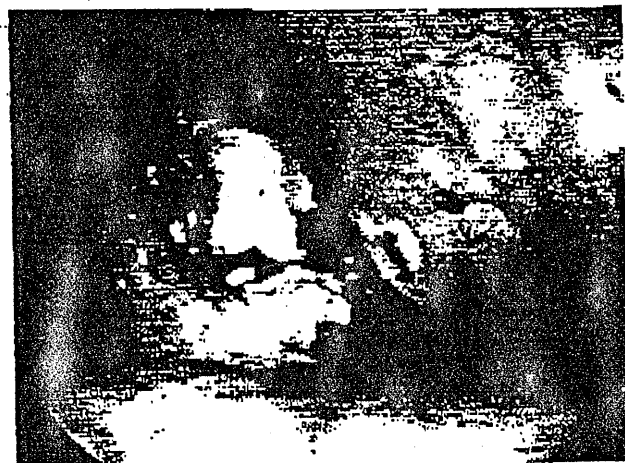


FIG. 3. Left-sided endometrioma.

## NEZHAT ET AL.

First, operative laparoscopy during pregnancy provides the surgeon with a panoramic view of the pelvic organs, thus reducing intraoperative uterine manipulation. A less traumatic procedure might reduce the risk of uterine irritability, resulting in a decreased incidence of postoperative spontaneous abortion or premature labor. Second, lessening postoperative pain reduces fetal exposure to narcotics. Finally, rapid return to full activity could reduce the incidence of maternal thrombophlebitis. As operative laparoscopy becomes more utilized for benign abdominal and pelvic conditions, pregnant women should be offered this option.

## REFERENCES

1. Nezhat C, Winer W, Nezhat F: Laparoscopic removal of dermoid cysts. *Obstet Gynecol* 1989;73:278.
2. Cunningham FG, MacDonald PC, Gant NF: *Williams Obstetrics*, 18th ed. Norwalk, CT: Appleton & Lange, 1989. pp 391-392.
3. Thornton JG, Wells M: Ovarian cysts in pregnancy: Does ultrasound make traditional management inappropriate? *Obstet Gynecol* 1987;69:717-721.
4. Schreiber JH: Laparoscopic appendectomy in pregnancy. *Surg Endosc* 1990;4:100-102.
5. Barnett MB, Liu DT: Complications of laparoscopy during early pregnancy (Letter). *Br Med J* 1974;1(903):328.

Address reprint requests to:  
Camran Nezhat, M.D.  
Fertility and Endoscopy Center  
and Laser Endoscopy Institute of Atlanta  
5555 Peachtree Dunwoody Road  
Atlanta, GA 30345