

Nov 1994

Instruments & Methods

LAPAROSCOPIC SACRAL COLPOPEXY FOR VAGINAL VAULT PROLAPSE

Ceana H. Nezhat, MD, Farr Nezhat, MD, and Camran Nezhat, MD

Laparoscopic sacral colpopexy can be used to treat vaginal vault and genital prolapse. After preparation, the vaginal apex is attached to the sacrum over the third and fourth sacral vertebrae using mesh. (*Obstet Gynecol* 1994;84:885-8)

Vaginal vault prolapse occurs when the apex of the vagina descends below the introitus, turning the vagina inside out. It is uncommon in the United States, occurring in only 900-1200 women annually.¹ Among the surgical techniques proposed to prevent and correct this condition is abdominal sacral colpopexy with the interposition of a synthetic suspensory hammock between the prolapsed vaginal vault and anterior surface of the sacrum.²⁻⁴ However, this technique usually requires a midline abdominal incision, abdominal packing, and extensive bowel manipulation, and has the potential for morbidity, such as infection, wound separation or dehiscence, and ileus or bowel obstruction.⁴ To minimize these drawbacks, we modified sacral colpopexy to be performed laparoscopically.

From the Department of Obstetrics and Gynecology, Mercer University School of Medicine, Macon, Georgia; and the Department of Obstetrics and Gynecology, Stanford University School of Medicine, Stanford, California.

Materials and Methods

After the induction of general endotracheal anesthesia, the patient is placed in the Trendelenburg position and tilted to the left to move the bowel from the operating field.⁵ After a thorough evaluation of the peritoneal cavity and completion of other procedures, such as hysterectomy or lysis of adhesions,⁵ the vaginal vault is elevated by a sponge on a ring forceps. The vaginal apex is prepared by removing peritoneum and connective tissue until the vaginal fascia and scar are seen (Figure 1). The bladder is dissected from the anterior vaginal wall and the rectum from the posterior vaginal wall so that approximately 4 cm of the vaginal vault is exposed. If the vagina is opened in cases of hysterectomy or partial vaginectomy, pneumoperitoneum is maintained by placing an inflated surgical glove in the vagina.

The repair of a coexisting enterocele is performed laparoscopically by excising the sac; a modified Moschcowitz⁶ procedure follows. The rectosigmoid colon is pushed to the left side to expose the sacral area. The posterior parietal peritoneum at or below the sacral promontory is lifted with grasping forceps and incised to the level of S3 to S4, and the anterior sacral fascia is exposed. The peritoneal incision is extended from the right pararectal area downward toward the vagina through the presacral space (Figure 2). The following anatomic landmarks are identified: the right ureter, internal iliac artery and vein, descending colon, and presacral vessels.

A 2.5 x 10-cm piece of mersilene or Gore-Tex (W. L. Gore and Associates, Inc., Phoenix, AZ) mesh is rolled and introduced into the abdomen through the 10-mm suprapubic port. Three to five 1-0 Ethibond sutures (Ethicon, Inc., Somerville, NJ) are placed in a single row in the posterior vaginal wall apex (excluding the vaginal mucosa) from one lateral fornix to the other. Each suture is placed through one end of the mesh and tied loosely (Figure 3).

Other supportive measures in the lower vagina, such as anterior and posterior colporrhaphy, may be necessary for the lower and middle third of the vagina. If required, partial vaginectomy is accomplished. The mesh is sutured to the posterior vaginal wall with nonabsorbable suture and placed intraperitoneally before closing the vaginal cuff with delayed absorbable sutures.

The mesh is adjusted to hold the vaginal apex in the correct anatomic position without being tight. Two permanent sutures or staples are placed in the longitudinal ligaments of the anterior surface of the sacrum, approximately 1 cm apart in the midline over the third and fourth sacral vertebrae (Figure 4). The peritoneum

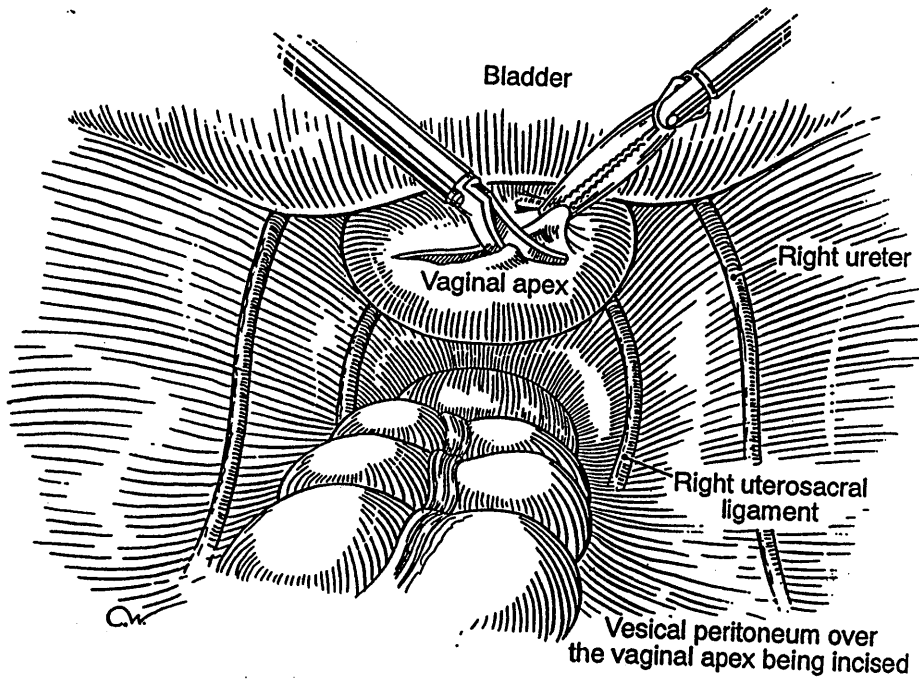


Figure 1. The vesical peritoneum over the vaginal apex is incised, and the vaginal apex is cleaned.

is then sutured over the graft from the sacrum toward the vagina. Usually, only a small segment of the graft cannot be covered. The serosa of the tail of the bladder (posterior peritoneal fold) and the superficial serosa of the sigmoid colon are used to cover the exposed mesh completely (Figure 5). If indicated, laparoscopic urethropexy is performed at this point.

Postoperatively, the patient is instructed to limit her activity and avoid intercourse for 6 weeks and strenuous exercise and heavy lifting for 2 months. Diet is advanced as tolerated, and a mild laxative is prescribed to prevent constipation.

Results

This procedure has been performed in 15 women; 12 had symptomatic post-hysterectomy vaginal vault prolapse and wished to preserve their coital capacity, and three had complete genital prolapse requiring hysterectomy and prophylactic vault suspension. The average age was 60 years (range 48–76), average gravidity 4.2 (range 1–11), and average parity 3.5 (range 1–9). All women had pelvic disease or required additional pro-

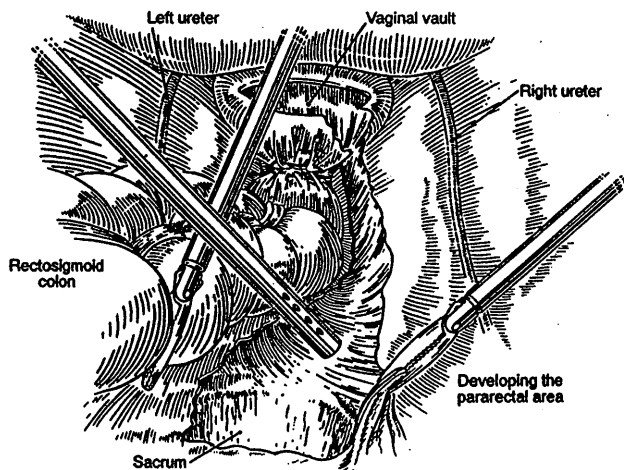


Figure 2. Using hydrodissection and the CO₂ laser, the right pararectal and presacral spaces are developed.

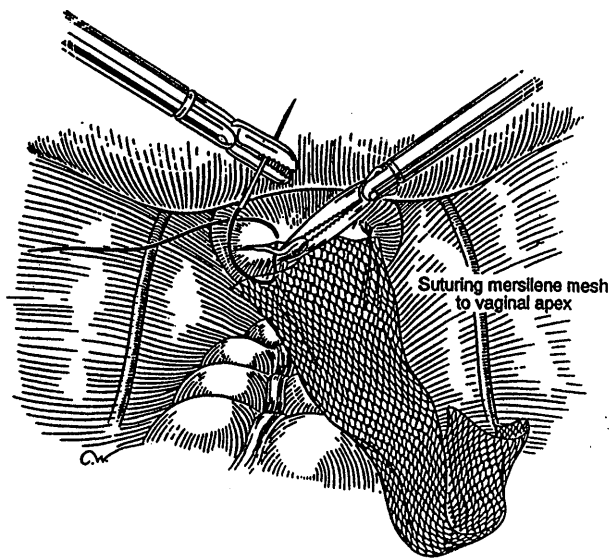
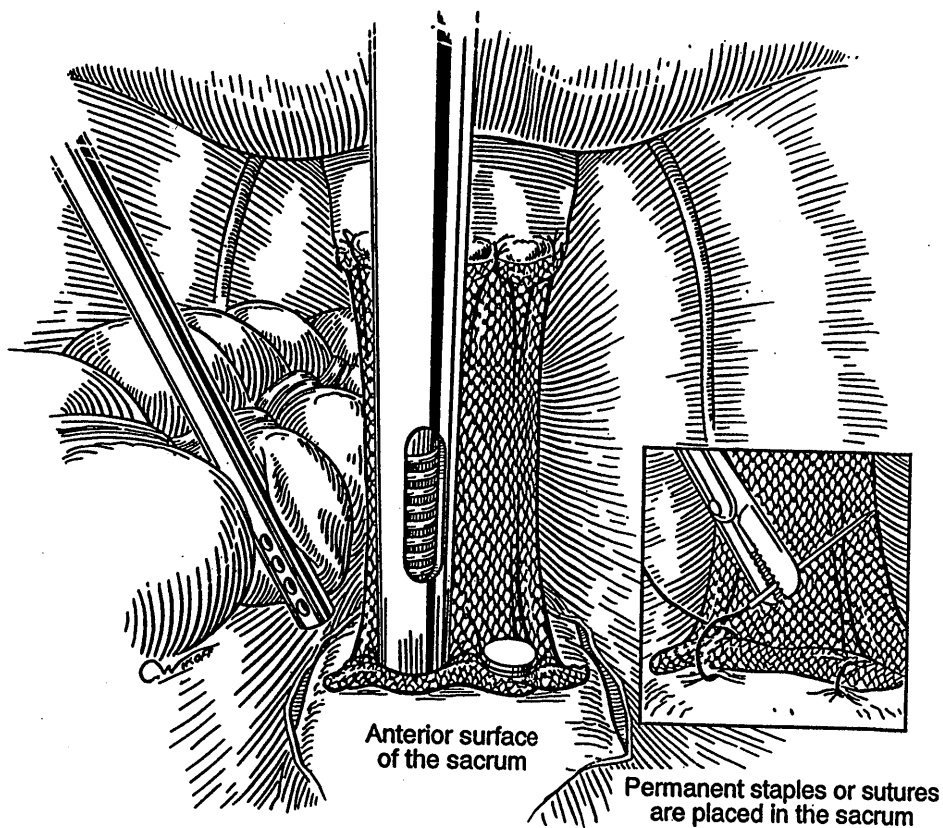


Figure 3. The mersilene mesh is tied very loosely to the vaginal apex.

Figure 4. Two permanent sutures or staples are placed in the presacral ligament approximately 1 cm apart in the midline over the third and fourth sacral vertebrae.



cedures, which excluded them from consideration for a vaginal approach.

All patients had recurrent mucosal irritation. Eight previously underwent reconstructive pelvic operations,

and three had recurrent prolapse after previous sacrospinous ligament fixation. All patients received at least 8 weeks of estrogen replacement therapy preoperatively. All were told about the novelty of the technique and the possibility of a need for laparotomy. It was stressed that the principles of the operation were not new but that the approach through the laparoscope was a new technique. All patients received one preoperative intravenous injection of 2 g of first-generation cephalosporin and one postoperative dose.

The operating time, which ranged from 105–320 minutes (mean 170), decreased with experience. Estimated blood loss ranged from 50–800 mL, with a mean of 226 mL. All procedures but one were completed laparoscopically. During the application of presacral staples to anchor the mesh to the sacrum, one patient had substantial bleeding that required laparotomy.

Ten women were discharged on the second postoperative day; four women were discharged on the third day (mean 2.28). The woman who had laparotomy was discharged on the seventh postoperative day and is not included in the mean. Patients have been followed for 3–40 months; all have indicated complete relief of their symptoms, with excellent vaginal vault support and no coital difficulty.

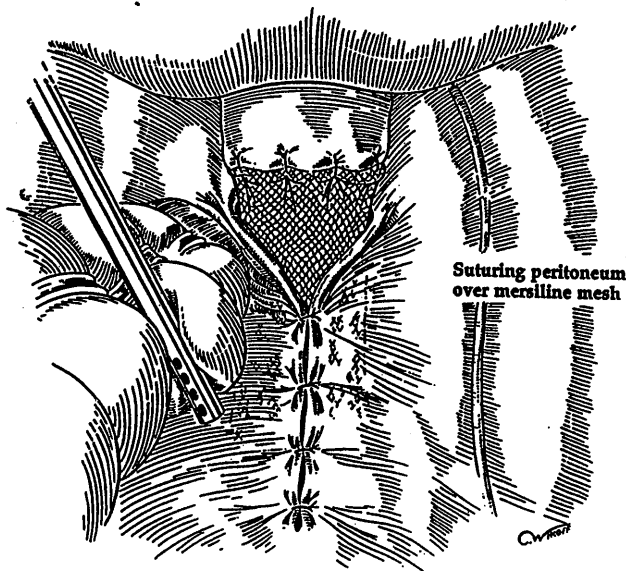


Figure 5. Sutures or staples can be used to retroperitonealize the mesh.

Discussion

The introduction of videolaparoscopy and videolaser-scopy has revolutionized chest and abdominal surgery.⁸ Abdominal colpopexy by suspending a mesh hammock between the prolapsed vaginal vault and sacrum in carefully selected patients has been reported with good results.^{2,7,9} We modified this operation laparoscopically, following the principles of abdominal colpopexy to restore correct anatomic position of the vault. This technique may prove to be an alternative to abdominal sacral colpopexy for patients who are not candidates for a vaginal approach.

References

1. Dunton JD, Mikuta J. Posthysterectomy vaginal vault prolapse. *Postgrad Obstet Gynecol* 1988;8:1-6.
2. Arthur HG, Savage D. Uterine prolapse and prolapse of vaginal vault treated by sacral hysteropexy. *J Obstet Gynaecol Br Emp* 1957;64:355-60.
3. Randall CL, Nichols DH. Surgical treatment of vaginal inversion. *Obstet Gynecol* 1971;38:327-32.
4. Symmonds RE, Williams TJ, Lee RA, Webb MJ. Post-hysterectomy enterocele and vaginal vault prolapse. *Am J Obstet Gynecol* 1981; 140:852-9.
5. Nezhat C, Nezhat F, Nezhat C. Operative laparoscopy (minimally invasive surgery): State of the art. *J Gynecol Surg* 1992;8:111-41.

6. Nichols DH. Surgery for pelvic floor disorders. *Surg Clin North Am* 1991;71:927-46.
7. Feldman GB, Birnbaum SJ. Sacral colpopexy for vaginal vault prolapse. *Obstet Gynecol* 1979;53:399-401.
8. Nezhat C. Videolaser-scopy: A new modality for treatment of diseases of the reproductive organs. *Colposc Gynecol Laser Surg* 1986;2:221-4.
9. Timmons MC, Addison WA, Addison SB, Cavenar MG. Abdominal sacral colpopexy in 163 women with posthysterectomy vaginal vault prolapse and enterocele. *J Reprod Med* 1992;37:323-7.

Address reprint requests to:

Camran Nezhat, MD
Stanford University
900 Welch Road
Suite 403
Stanford, CA 94304

Received November 24, 1993.

Received in revised form June 2, 1994.

Accepted June 16, 1994.

Copyright © 1994 by The American College of Obstetricians and Gynecologists.