

Laparoscopic proctectomy for infiltrating endometriosis of the rectum

Farr Nezhat, M.D.*†
Camran Nezhat, M.D.*†‡
Earl Pennington, M.D.*

Center for Special Pelvic Surgery, Endometriosis Clinic, Fertility and Endoscopy Center, Atlanta,
and Mercer University, Macon, Georgia

Five percent of cases of endometriosis involve the colon and 76% of these cases involve the rectum or rectosigmoid area. Deeply infiltrating rectal lesions traditionally required open laparotomy for bowel resection and reanastomosis, increasing morbidity and extending recovery. Recently, laparoscopic assisted bowel resections have been described, and the laparoscope's use in gastrointestinal surgery is increasing (1). Techniques for laparoscopic assisted bowel resection have been limited to the anterior wall or areas for resection and anastomosis through a separate, smaller abdominal incision (1, 2). The latter procedure is not recommended for rectal lesions because the rectum is not long enough to be brought up to the abdominal wall (1). We have previously reported on the technique of anterior rectal wall resection and reanastomosis (2). Now we have developed a technique for total rectal wall resection combining advanced operative laparoscopy to mobilize and cut the rectum so that it can be prolapsed through the anal canal, resected, replaced into the pelvis, and reanastomosed.

CASE REPORT

A 28-year-old woman, gravida 0, para 0, presented with a history of severe pelvic and rectal pain. She

Received September 17, 1991; revised and accepted January 9, 1992.

* Center for Special Pelvic Surgery, Endometriosis Clinic, Fertility and Endoscopy Center.

† Department of Obstetrics and Gynecology, Mercer University.

‡ Reprint requests: Camran Nezhat, M.D., 5555 Peachtree Dunwoody Road, Suite 276, Atlanta, Georgia 30342.

was diagnosed as having severe pelvic endometriosis with rectal involvement and stricture before admission. At the time of admission, she presented with pronounced cul-de-sac tenderness and nodularity along with a palpable rectal narrowing.

Operative videolaseroscopy described in detail elsewhere was performed on the patient after mechanical and antibiotic bowel preparation (2). Multiple pelvic adhesions and extensive endometriosis involving the posterior cul-de-sac, rectovaginal septum, and ureters were noted. Lysis of adhesions, vaporization, and excision of endometriosis were accomplished using the CO₂ laser and hydrodissection (3). Because of extensive involvement with endometriosis, left ureterolysis had to be performed to separate the rectosigmoid colon from the distal portion of the ureter using techniques described before. Both ureters were identified and preserved (3).

The dissection was carried into the rectovaginal septum, freeing the rectum from the vagina. A 4 × 3 × 3 cm endometriotic nodule was noted in the anterior rectal wall along with narrowing and fibrosis of the lumen. Laparoscopic examination suggested deep penetration into the bowel wall, which was confirmed by proctosigmoidoscopic examination.

Segmental resection of the rectal wall was accomplished in the following manner:

1. The rectum was completely mobilized to allow prolapse of the lesion transanally. An assistant delineated the rectovaginal septum by performing simultaneous digital examinations of the rectum and vagina (3). The CO₂ laser was then used to mobilize the rectum down to the pelvic floor. In a similar

fashion, the rectal mesentery was dissected laterally with the CO₂ laser (2, 3). This dissection required division of the lateral stalks. Hemostasis was obtained using bipolar electrocautery. Posteriorly, the avascular presacral space was dissected down to the level of the levator ani muscles (Fig. 1).

2. The bowel was divided proximal to the lesion and prepared for anastomosis. The mesentery was divided with CO₂ laser, and bipolar cautery was used to divide major blood vessels without vascular clips or suture (3).

3. The proximal end of the bowel was pulled through the rectal stump out the anus. A 2-0 polypropylene (Ethicon, Somerville, NJ) purse-string suture was inserted into the end of the proximal bowel. This was used to secure the opposing anvil of a no. 33 ILS stapler (Ethicon). The anvil was separated from the gun, secured with purse-string suture, and then replaced transanally into the pelvis along with the proximal bowel (Fig. 2).

4. The rectal stump containing the endometrial lesion and fibrosis was then prolapsed out the anus

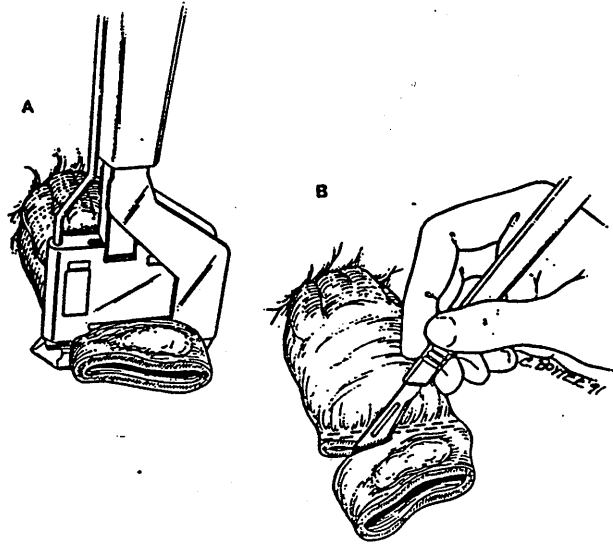


Figure 2 (A), RL60 (Ethicon, Somerville, NJ) is used to resect the lesion off the distal colon. (B), A portion of colon is being removed.

by grasping the transected end of the rectal stump with Babcock (Baxter Mueller, Chicago, IL) clamps and pulling it through the anal canal (Fig. 2). The rectum was stapled shut with a RL60 linear stapler (Ethicon), and the rectal specimen, 8 cm in length, was resected and sent to surgical pathology (Fig. 2).

5. The rectal stump was reduced inside the pelvis and an end-to-end double stapled anastomosis was performed with the no. 33 ILS stapler (Ethicon). A trocar in the gun was passed through the stapled end of the rectum. The laparoscope was then used to attach the opposing anvil in the proximal bowel. The bowel ends were approximated, and the stapler was fired to complete the anastomosis. Intact "donut" margins were present (Fig. 3).

6. A proctoscope was used to inspect the anastomosis that was grossly intact without anastomotic bleeding. The pelvis was filled with saline through the laparoscope and visualized as air was insufflated into the rectum from the proctoscope. No bubbling was noted, demonstrating anastomotic integrity. The procedure took 200 minutes with an estimated blood loss of <100 mL.

RESULTS

Pathology demonstrated multiple endometrial lesions and fibrosis. The rectal specimen contained an endometrial implant extending into the muscularis propria of the rectum.

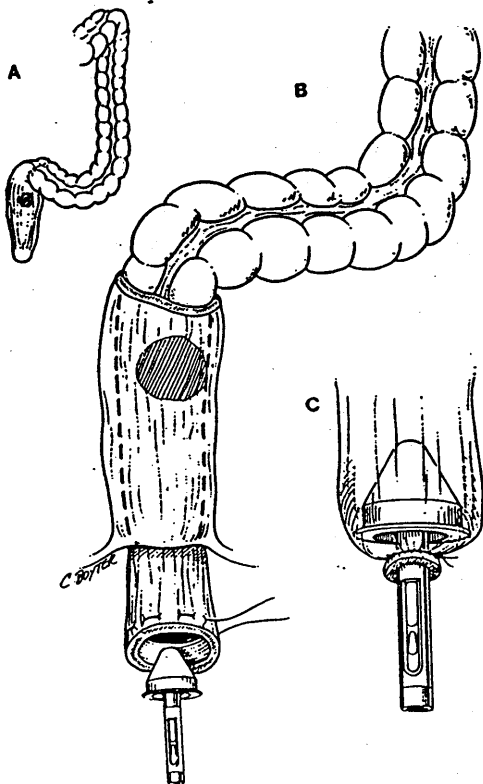


Figure 1 (A), Fibrosis, narrowing and endometriosis of lower colon. (B), Proximal colon has been prolapsed anally via the distal colon. Purse-string suture has been placed. (C), Anvil is ready to be inserted.

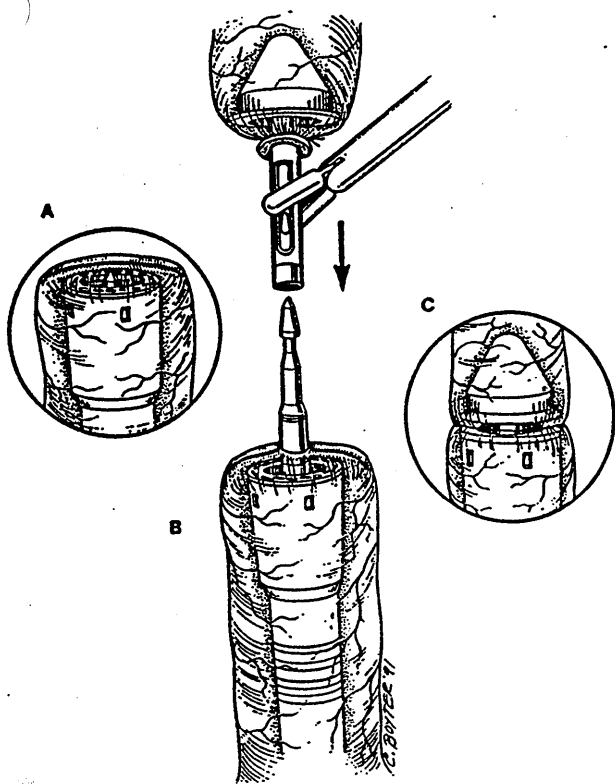


Figure 3 (A), Distal portion of colon is being placed into the pelvis. (B), Distal and proximal portions of the bowel are being attached. (C), Reanastomosis is complete.

The patient had an unremarkable postoperative course passing flatus and moving her bowels on the 3rd postoperative day. She was discharged from the hospital on postoperative day 5.

DISCUSSION

A recent report by Coronado et al. (4) on their experience with 77 cases of deep rectal endometriosis demonstrated a favorable outcome in treatment efficacy as well as minimal morbidity and mortality with a team of gynecologists and general surgeons. When deeply invasive endometriosis requires bowel resection, a formal laparotomy has been necessary. Transperineal proctectomy with reanastomosis is an accepted, safe procedure. However, fixation of the rectum by rectal mesentery, lateral stalks, and rectovaginal adherence renders it applicable only in selected cases of idiopathic rectal prolapse. These are cases in which the points of fixation have weakened to an extent allowing the rectum to spontaneously prolapse through the anal canal. In this patient, us-

ing the laparoscope, we excised or vaporized the pelvic endometriosis, and created an iatrogenic rectal prolapse by using the laparoscope to fully mobilize the rectum from its fascial and vascular attachments. This allowed us to perform an extracorporeal transanal resection of the diseased segment of the rectum followed by double-stapled reanastomosis of the bowel. This double-staple technique is accepted procedure for low colorectal anastomosis.

Although the patient tolerated this unique procedure well and without complication, caution with regard to application and technique must be considered. First, as with all new procedures, there are no data to establish its safety. Additional procedures with long-term follow-up are necessary to establish its efficacy and safety. Second, this procedure was performed for benign disease, and the surgical margins obtained in this patient may not be adequate for a malignant process. Finally, dissection of severe endometriosis, rectal mobilization, and bowel anastomosis are delicate and tedious procedures. They should only be undertaken by experienced surgeons with expertise in operative laparoscopy, pelvic dissection, and bowel surgery.

SUMMARY

Proctectomy for deep endometriosis of the rectal wall was performed without laparotomy. Although laparoscopic pelvic surgery and transperineal proctectomy with primary double-stapled anastomosis are established procedures in gynecological and gastrointestinal surgery, this is the first reported case in which these procedures are combined to mobilize the rectum and perform an extracorporeal transanal rectal resection and anastomosis.

Key Words: Bowel resection, operative laparoscopy, laparoscopy, videolaseroscopy, CO₂ laser, endometriosis, partial proctectomy, pelvic pain.

ADDENDUM

Between the time this article was submitted and January, 1992, we performed an additional 15 similar procedures. Only 1 required laparotomy. Complete vaporization and rectal resection were accomplished laparoscopically in this case; however, the proximal bowel was dilated and patulous and an adequate purse-string could not be placed transanally. Laparotomy to complete the anastomosis was performed without complication. Details of these operative

procedures are available from the authors upon request.

REFERENCES

1. Cooperman AM, Zucker KA. Laparoscopic guided intestinal surgery. In: Zucker KA, editor. Surgical laparoscopy. St. Louis: Quality Medical Publishers, 1991.
2. Nezhat C, Pennington E, Nezhat F, Silfen SL. Laparoscopically assisted anterior rectal wall resection and reanastomosis for deeply infiltrating endometriosis. *Surg Lapar Endosc* 1991;1:106-8.
3. Nezhat C, Silfen SL, Nezhat F, Martin D. Surgery for endometriosis. *Curr Opin Obstet Gynecol* 1991;3:385-93.
4. Coronado C, Franklin RR, Lotze EC, Bailey HR, Valdes CT. Surgical treatment of symptomatic colorectal endometriosis. *Fertil Steril* 1990;53:411-6.