

May 1994

LAPAROSCOPIC REPAIR OF A VESICOVAGINAL FISTULA: A CASE REPORT

Ceana H. Nezhat, MD, Farr Nezhat, MD, Camran Nezhat, MD, and Howard Rottenberg, MD

Background: Operative laparoscopy was performed for the management of ovarian remnant syndrome involving the bladder, bowel, vagina, and ureters, and requiring extensive dissection. A vesicovaginal fistula developed postoperatively.

Case: Because of the complexity and location of the fistula, a vaginal approach was not appropriate. Using techniques of videolaparoscopy, videocystoscopy, and operative laparoscopy, the fistula was repaired.

Conclusion: In experienced hands, endoscopic management of complex vesicovaginal fistulas may be an alternative to the traditional abdominal approach. (*Obstet Gynecol* 1994;83:899-901)

Vesicovaginal fistulas may be treated by various surgical techniques, depending on their etiology and location and the surgeon's specialty.¹ Small, simple vesicovaginal fistulas unresponsive to nonsurgical management are usually easy to repair.² Generally, the edges of the fistula are removed and the defect is closed. Latzko's technique³ is the most commonly used vaginal approach. However, complex fistulas often have significant structural changes in the perifistular tissue and may be close to the bladder neck or urethral meatus. Lee et al⁴ recommended an abdominal approach for the following indications: 1) inadequate exposure because of a high or retracted fistula in a narrow vagina, 2) proximity of the fistula to the ureter, 3) associated pelvic pathology, and 4) multiple fistulas. In complicated cases, a combined transabdominal and transvaginal approach has been recommended.⁵ We report laparoscopic repair of a vesicovaginal fistula following laparoscopic treatment of ovarian remnant syndrome, which required resection of portions of the bladder, bowel, and vagina, and extensive ureterolysis. In this case, the fistula was close to the ureter and high in the bladder, and the woman had a narrow vagina.

From the Center for Special Pelvic Surgery, Atlanta; and the Department of Obstetrics and Gynecology, Mercer University School of Medicine, Macon, Georgia.

Case Report

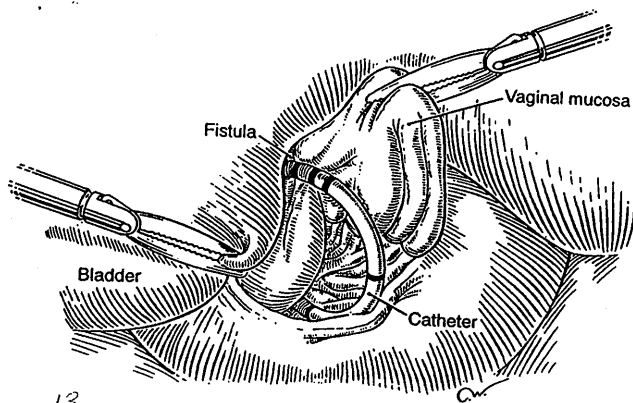
A 45-year-old woman underwent laparoscopic excision of an ovarian remnant.⁶ This required extensive bilateral ureterolysis, and resection and repair of a 2-cm portion of the rectosigmoid colon.⁷ It was also necessary to remove a 1.5-2-cm portion of the posterior bladder wall, which was repaired laparoscopically as previously described.⁸

Postoperatively, the patient developed a vesicovaginal fistula. She presented with a watery discharge from the vagina. No fistula was seen on speculum examination, but it was suspected based on vaginal tampon and blue dye test. Cystogram and intravenous pyelogram demonstrated a posterior vesicovaginal fistula projected from the upper third of the bladder, with no extravasation from the ureters. Cystoscopy revealed a vesicovaginal fistula approximately 1 cm in diameter located posterior and superior to the trigone, left of the midline. The fistula was quite high and could not be reached by a finger in the vagina. We attempted to manage this fistula conservatively by reinserting the Foley catheter and prescribing an antibiotic. However, after 3 weeks of conservative management, a cystogram confirmed that the fistula had not resolved.

Different options were discussed with the patient. Prolonged expectant management was not acceptable to her. Because of the complexity, location, and condition of the fistula, a vaginal approach was not appropriate. We offered a transabdominal approach by laparoscopy, following the same principles as laparotomy. She was told of our experience with laparoscopy, the possibility of conversion to laparotomy, the experimental nature of the procedure, and the advantages and disadvantages of both procedures. After consulting one other gynecologist and two urologists, she chose the laparoscopic approach over a laparotomy, possibly combined with a vaginal approach. She was aware that, to our knowledge, this would be the first attempt to manage this type of fistula laparoscopically.

Two weeks later (12 weeks postoperatively), videolaparoscopy was performed as previously described.⁹ We followed as closely as possible the principles outlined by Moir¹⁰ for fistula repair: 1) suitable equipment and lighting, 2) adequate exposure during the operation, 3) excision of fibrous tissue from the edges of the fistula, 4) approximation of edges without tension, 5) use of suitable suture material, and 6) efficient postoperative bladder drainage.

In summary, one 10-mm infraumbilical incision was made to insert the videolaparoscope coupled with the CO₂ laser. Three 5-mm incisions were made in the lower abdomen to introduce the suction-irrigator probe, grasping forceps, and bipolar forceps.⁹ A thorough abdominal and pelvic cavity evaluation revealed many fewer adhesions in this area than were noted during the previous laparoscopy. Adhesions around the bladder dome and posterior cul-de-sac were easily lysed. A simultaneous cystoscopy was performed, and both ureters were catheterized to help identify and protect them during excision and closure of the fistula. The fistula was readily identified in the posterior bladder wall superior to the trigone (Figure 1). A ureteral catheter was pulled



13

Figure 1. The fistula is identified in the posterior bladder wall superior to the trigone.

through the fistula into the vagina to facilitate identification during excision.

A digital rectovaginal examination was performed to exclude rectal involvement. The bladder was severely adherent to the vagina over the apex. Using the CO₂ laser, an opening was made in the vagina away from the bladder and rectum. An inflated glove in the vagina helped maintain pneumoperitoneum.

Using a grasping forceps, we elevated the anterior vaginal wall and easily identified the fistula with the help of the catheter, which also served as a landmark for the posterior bladder wall. The bladder was filled with water, and using the CO₂ laser through the laparoscope, a cystostomy was performed above the fistula. The water was evacuated as the bladder was distended by the pneumoperitoneum from the cystostomy. The fistula tract, vesicovaginal space, and ureters were easily observed laparoscopically (Figure 2). Under direct observation, the vesicovaginal space was developed laparoscopically using the CO₂ laser and hydrodissection. The bladder was freed posteriorly from the vaginal wall (Figure 3). The bladder fistula was identified, held with a grasping forceps, and excised using the CO₂ laser (Figure 4). Adequate bladder dissection and mobilization were performed to eliminate tension upon suturing.

Both the vagina and bladder were closed laparoscopically.

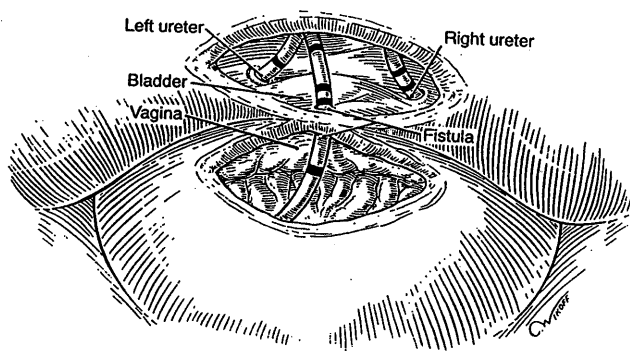


Figure 2. The fistula tract, vesicovaginal space, and ureters are easily observed laparoscopically.

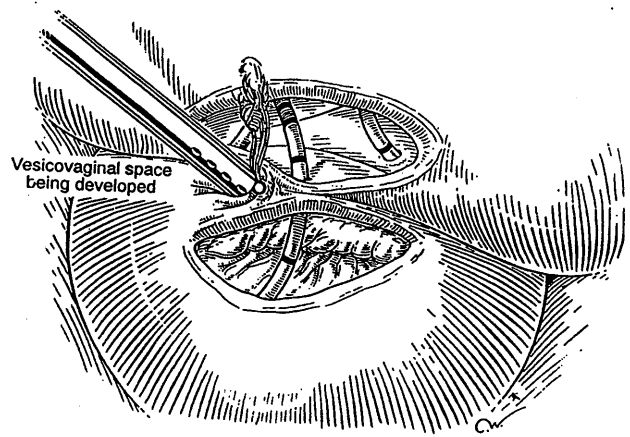


Figure 3. The bladder is freed posteriorly from the vaginal wall.

First, the vaginal wall opening of approximately 1.5 cm was repaired with one layer of interrupted polyglactin suture (Figure 5). The bladder was then repaired with one layer of four interrupted 1-0 endoknot Vicryl sutures (Ethicon, Somerville, NJ) using extracorporeal knotting. This allowed closure of the vagina and bladder in separate planes. A thorough evaluation was performed to ensure complete hemostasis of the vesicovaginal space and fistula area. A peritoneal flap was obtained superior and lateral to the bladder dome close to the round ligament and diverted toward the bladder base. The flap was used to separate the vesicovaginal space, and it was secured with two interrupted Vicryl sutures. The dissected peritoneal area was left to heal secondarily. No intraperitoneal drainage was used. The operative time was 85 minutes including the cystoscopic portion, and total blood loss was less than 100 mL. Following the procedure, a suprapubic catheter was inserted and the ureteral catheters were removed.

The following morning, the patient was discharged. Prophylactic antibiotics and conjugated estrogen tablets were prescribed. She was instructed to return in 2 weeks. On postoperative day 10, the Foley catheter became clogged and was removed. A cystogram was performed, and there was no evidence of fistula. Following the surgery, the patient was

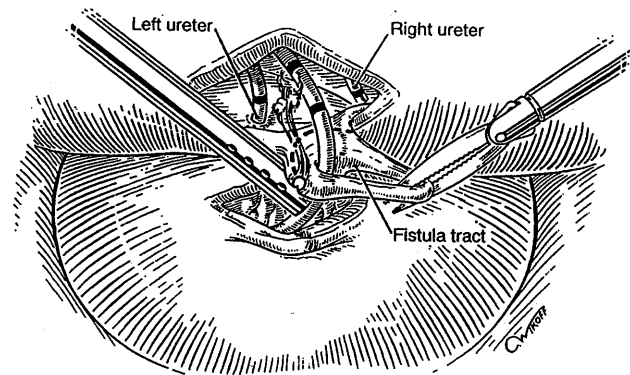


Figure 4. The bladder fistula is identified, held with a grasping forceps, and excised using the CO₂ laser.

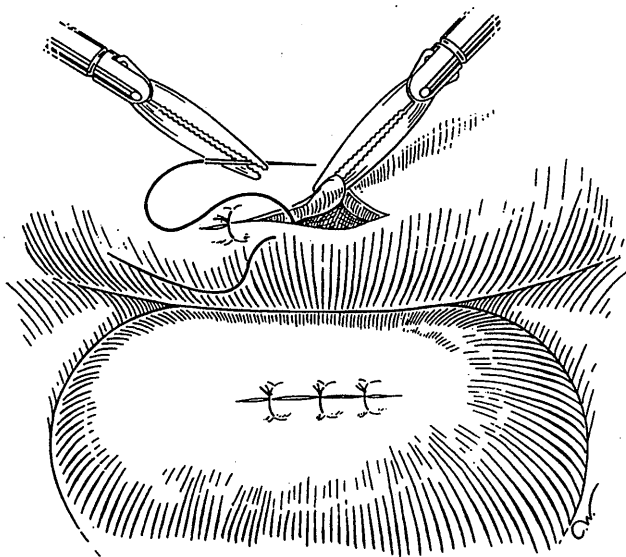


Figure 5. The vaginal wall repair is complete and the bladder opening repair is in progress.

continent except for urinary frequency, which persisted for about 2 weeks. She has been asymptomatic for 10 months.

Discussion

Laparoscopy can be an alternative to laparotomy for managing several pathologic disorders.⁹ Proposed advantages include magnification during the procedure and shorter hospital stay and postoperative recovery. Because of the location of the fistula, we preferred a laparoscopic as opposed to a vaginal approach. The exposure and magnification afforded by videolaparoscopy provided fast and direct access to the fistula. The videocystoscope enhanced the access, eliminating the need for bladder dome incision for exposure. The fistula was resected under direct visualization without ureteral trauma. We successfully performed an edge-to-edge anastomosis of the resected fistula without difficulty. The magnification and exposure allowed meticulous and atraumatic bladder dissection and fistula resection. The bladder capacity was not significantly reduced. There was no tension in the repair, and it was vascularized. In experienced hands, this technique may be an alternative to the combined transabdominal and transvaginal approach.

Addendum

Since submitting this case report, we have managed two additional vesicovaginal fistulas, both following abdominal hysterectomy performed elsewhere. The repairs were accomplished as described above with good results.

References

1. Drutz HP. Urinary fistulas. *Obstet Gynecol Clin North Am* 1989;16:911-21.
2. Falk HC, Orkin LA. Nonsurgical closure of vesicovaginal fistulas. *Obstet Gynecol* 1957;9:538-41.
3. Latzko W. Behandlung Hochsitzender Blasen-und Mastdarmscheidenfisteln nach Uteruseztipation mit hohem Schedienverschluss. *Zentralbl Gynakol* 1914;38:904-11.
4. Lee RA, Symmonds RE, Williams TJ. Current status of genitourinary fistula. *Obstet Gynecol* 1988;72:313-9.
5. Taylor JS, Hewson AD, Rachow P. Synchronous combined transvaginal repair of vesicovaginal fistulas. *Aust N Z J Surg* 1980;50:23-5.
6. Nezhat C, Nezhat F. Operative laparoscopy for the management of ovarian remnant syndrome. *Fertil Steril* 1992;57:1003-7.
7. Nezhat C, Nezhat F, Ambroze W, Pennington E. Laparoscopic repair of small bowel, colon, and rectal endometriosis: A report of twenty-six cases. *Surg Endosc* 1993;7:88-9.
8. Nezhat F, Nezhat C. Laparoscopic segmental bladder resection for endometriosis: A report of two cases. *Obstet Gynecol* 1993;81:882-4.
9. Nezhat C, Nezhat F, Nezhat C. Operative laparoscopy (minimally invasive surgery): State of the art. *J Gynecol Surg* 1992;8:111-41.
10. Moir JC. Principles and methods of treatment of vesicovaginal fistulae. In: Moir JC, Chasser J. *The vesico-vaginal fistula*. London: Bailliere, Tindall and Cassell, 1967:52.

Address reprint requests to:
Camran Nezhat, MD
300 Pasteur Road
Stanford, CA 94305

Received April 12, 1993.
Received in revised form July 20, 1993.
Accepted July 21, 1993.

Copyright © 1994 by The American College of Obstetricians and Gynecologists.